

Platelets rich plasma versus minoxidil 5% in treatment of alopecia areata: A trichoscopic evaluation

Moustafa A. El Taieb¹ | Hassan Ibrahim² | Essam A. Nada³ | Mai Seif Al-Din⁴

¹Department of Dermatology, Venereology and Andrology, Aswan University, Aswan, Egypt

²Department of Dermatology, Venereology and Andrology, South Valley University, Qena, Egypt

³Department of Dermatology, Venereology and Andrology, Sohag University, Sohag, Egypt

⁴Department of Dermatology, Qina General Hospital, Qena, Egypt

Correspondence

Moustafa A. El Taieb, Department of Dermatology, Venereology and Andrology, Aswan University, Aswan, Egypt.
Email: moustafa.eltaib@aswu.edu.eg; musmus22@yahoo.co.uk

Abstract

Alopecia areata is a common cause of nonscarring alopecia that occurs in a patchy, confluent, or diffuse pattern. Dermoscopy is a noninvasive technique for the clinical diagnosis of many skin diseases. Topical minoxidil solution 5% and platelet rich plasma are important modalities used in treatment of alopecia areata. We aimed to evaluate the efficacy of PRP versus topical minoxidil 5% in the treatment of AA by clinical evaluation and trichoscopic examination. Ninety patients were allocated into three groups; the first was treated with topical minoxidil 5% solution, the second with platelets rich plasma injections, and the third with placebo. Diagnosis and follow up were done by serial digital camera photography of lesions and dermoscopic scan before and every 1 month after treatment for 3 months. Patients treated with minoxidil 5% and platelets rich plasma both have significant hair growth than placebo ($p < .05$). Patients treated with platelets rich plasma had an earlier response in the form of hair regrowth, reduction in short vellus hair and dystrophic hair unlike patients treated with minoxidil and control ($p < .05$). In conclusion, platelets rich plasma is more effective in the treatment of alopecia areata than topical minoxidil 5% as evaluated by clinical and trichoscopic examination.

KEYWORDS

alopecia areata, platelets rich plasma, trichoscopy

1 | INTRODUCTION

Alopecia areata (AA) is the most frequent cause of inflammation-induced hair loss with prevalence from 0.1 to 0.2%. It has no age nor sex predilection (Gilhar, Etzioni, & Paus, 2012). Hair loss in AA represents a disorder of hair follicle cycling (Paus, 1996). During the development of AA, exogen often occurs before anagen is renewed or when anagen is dystrophic. This results in a state called kenogen where no visible hair fiber is left in the hair follicle (McElwee & Sinclair, 2008). So, AA-affected skin can be said to be in a state of kenogen (Alkhalifah, Alsantali, Wang, McElwee, & Shapiro, 2010).

Many theories were implicated in pathogenesis of AA, such as an autoimmune lymphocytic attack of the hair (Wasserman, Guzman-Sanchez, Scott, & McMichael, 2007), genetic basis (Alkhalifah et al., 2010), and environmental factors (Rodríguez & Duvic, 2008).

Clinically, AA presents as a well-circumscribed patch of sudden hair loss. It affects any hair bearing area. The most common affected site is the scalp (Alkhalifah et al., 2010). Based on site and extent, AA can be classified into; diffuse, multi-ocularis, mono-ocularis, barbae,

totalis, universalis, ophiasis, and reticulate (Perera, Yip, & Sinclair, 2014; Zonunsanga, 2015).

The standard methods of diagnosis of hair loss disorders such as simple clinical inspection, pull test, and biopsy vary in sensitivity, reproducibility, and invasiveness. Dermoscopy is now considered as a valuable tool in diagnosis of variable skin lesions. Scalp dermoscopy (Trichoscopy) does not only facilitate diagnosis of hair disorders but also give clues about disease stage and progression (Tosti, 2007).

Trichoscopy allows the superimposition of the skin layers with the possibility to observe any surface or deep skin layer (Campos-do-Carmo & Ramos-e-Silva, 2008). The most common trichoscopic features of AA are yellow dots, micro-exclamation mark hairs, tapered hairs, black dots, broken hairs, and regrowing upright or regrowing coiled hairs (Abraham, Torres, & Azulay-Abulafia, 2010; Inui, 2011; Inui, Nakajima, & Itami, 2007; Inui, Nakajima, Nakagawa, & Itami, 2008; Mane, Nath, & Thappa, 2011). Trichoscopic characteristics have a clinical significance in AA for diagnosis and prognosis (Ross, Vincenzi, & Tosti, 2006; Rudnicka, Olszewska, Rakowska, & Slowinska, 2011).

TABLE 1 Patients' age, disease duration, type of alopecia, site of patchy alopecia, and dermoscopic findings in the three study groups

Variable	Minoxidil group	PRP group	Control group
Patient age (mean ± SD)	22.633 ± 9.97	19.76 ± 9.09	20.87 ± 8.09
Disease duration (mean ± SD)	27 ± 16.25	26 ± 17.18	28 ± 13.25
Type of alopecia (%)			
Alopecia areata	70	60	63.34
Alopecia totalis	6.7	10	13.33
Alopecia universalis	10	30	13.33
Ophiasis	13.3	0	10
Site of patchy Alopecia (%)			
Vertex	33.33	16.7	23.6
Occipital	28.67	55.5	35.2
Parietal	19	11.1	23.6
Frontal	19	16.7	17.6
Dermoscopic Findings (mean ± SD)			
GH 1	0.93 ± 0.82	1.1 ± 0.84	0.2 ± 0.4
GH 3	1.8 ± 1.1	1.8 ± 1.27	0.2 ± 0.61
YD1	1.7 ± 0.72	2.2 ± 0.76	2.4 ± 0.49
YD3	0.9 ± 1.09	1.1 ± 1.3	2 ± 0.9
SVH0	0.7 ± 0.7	1 ± 0.9	0.9 ± 0.71
SVH3	1.7 ± 0.77	0.4 ± 0.67	1.1 ± 0.84

PRP = platelets rich plasma; SD = standard deviation; GH1 = growing hair after 1 month; GH3 = growing hair after 3 months; YD1 = yellow dots after 1 month; YD3 = yellow dots after 3 months; SVH0 = short vellus hair at 0 point; SVH3 = short vellus hair after 3 months.

There is no novel therapy for AA. Topical and Intra-lesional corticosteroids, anthralin, immunotherapy, systemic corticosteroids, cyclosporine, and psoralen plus ultra violet-A light therapy are commonly used with varying success (Shumez, Prasad, Kaviarasan, & Deepika, 2015).

Topical minoxidil (2,4-diamino-6-piperidinopyrimidine-3-oxide) stimulates proliferation at the base of the hair bulb and differentiation above the dermal papilla (Amin & Sachdeva, 2013). Many mechanisms of action include vasodilatation, angiogenesis, enhanced cell proliferation, and potassium channel opening (Alsantali, 2011; Ito, 2012).

Platelets rich plasma (PRP) is an autologous preparation of platelets in concentrated plasma. Injection of PRP improves cutaneous ischemic conditions, increases vascular structures around hair follicles and induces the proliferation of dermal papilla cells by up regulating fibroblast growth factor 7 (FGF-7) (Li et al., 2012). Anagen-associated angiogenesis has been suggested as one of the important factors in active hair growth, due to the secretion of vascular endothelial growth factor by the keratinocytes of the outer root sheath and fibroblasts of the dermal papilla (Cervelli et al., 2014).

In the present study we evaluated the efficacy of PRP versus topical minoxidil 5% in the treatment of AA by clinical evaluation and trichoscopic examination.

1.1 | Patients

The present study is a randomized controlled study that was conducted in the department of Dermatology, South Valley University between June 2014 and May 2015. Ninety patients were included aged between 10 and 40 years, with no therapy for at least 3 months before study. Children aged less than 10 years, pregnant and lactating women, immunocompromised patients, and patients having active scalp inflammation are excluded from this study. Patients were randomized into three groups, 30 patients for each. First group was treated with topical minoxidil 5% twice daily (six pubs/time) as a monotherapy, second group was treated with PRP injections every 4-weeks and the third group received topical panthenol cream twice daily as a placebo.

1.2 | Methodology

A detailed history taking and physical examination were done for every patient. Clinical evaluation and follow up was performed with serial photos of the lesions using digital camera (Fujifilm 16 mega pixels, Japan). Dermoscopic scan using Dermoscope (Heine Beta Delta 20, Germany) was done before treatment and monthly after treatment for three months. Percentage of hair growth, short vellus hair and yellow dots were scaled and evaluated.

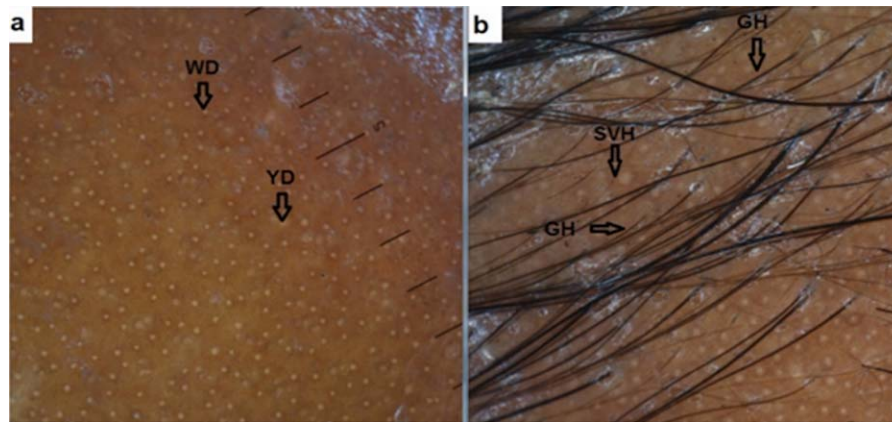


FIGURE 1 a and b: A Trichoscopy of a 15-years-old male patient had alopecia totalis of 3-years duration. (a) Before treatment shows numerous yellow dots (YD) and white dots (WD). (b) After 3 months of minoxidil 5% shows clusters of upright growing hair(GH), short vellus hairs (SVH), and less abundant yellow dots

For PRP preparation; 10 mL of blood was drawn from each patient and placed in two test tubes as 5 mL each. The collected blood was centrifuged at 3,000 rpm for 10 min, and blood separated into a red inferior phase and superior plasma supernatant phase. The PRP fraction was separated and suspended with calcium gluconate. The total volume of collected PRP was about 4 mL (Cervelli et al., 2014).

The mean blood platelet level is $200,000 \pm 75,000/\mu\text{L}$. Although the PRP platelet count has not been optimized, a platelet concentration of more than one million/ μL (approximately four to seven times the mean levels) is generally regarded as the therapeutically effective concentration of PRP (Arshdeep Kumaran, 2014). PRP injections were given under aseptic precautions. A total of three treatments were given to each patient at a monthly for 3 months.

1.3 | Ethical approval

The study was approved from local scientific and ethical committees at South Valley University. An informed written consent was obtained from each participant.

1.4 | Statistical analysis

Statistical analysis was performed using SPSS software (version 22.0). Description of quantitative variables as mean and standard deviation. Statistical significance was considered using Pearson Chi-square test (χ^2 .test). p value $\leq .05$ was considered statistically significant.

2 | RESULTS

Ninety patients with AA were recruited in the study. Patients were divided into three groups, 30 patients per each. The three groups were analyzed for therapeutic response with monthly follow up for 3 months. The mean duration of alopecia for all patients was (28 ± 16.15) months. Patients' age, duration and type of alopecia and dermoscopic findings in the three study groups are summarized in Table 1.

The first group included 16 females and 14 males. Regarding type of alopecia; patchy type was seen in 21 patients, 13 patients with single patch and eight with multiple patches. Alopecia totalis was seen in two patients. Ophiasis was seen in four patients and alopecia universalis was seen in three patients. In patchy alopecia, the most common sites involved were vertex and occipital region.

The second group included 15 males and 15 females. Patchy alopecia had the highest incidence being seen in 18 patients, 6 patients had single patch, and 12 had multiple patches. Three patients had alopecia totalis and nine patients had alopecia universalis. The most common site involved in patchy alopecia was occipital region.

The third group included 20 females and 10 males. The most common type was patchy alopecia seen in 19 patients, 9 patients had a single patch, and 10 had multiple patches. Four patients had ophiasis and four had alopecia universalis. Alopecia totalis seen in three patients. The most common site of patchy alopecia was the occipital region.

By clinical and dermoscopic evaluation of hair growth after treatment, minoxidil was more effective in patchy alopecia than other types of AA. A significant hair growth was observed with patchy alopecia (81%) than ophiasis (14%) and alopecia totalis (5%). No hair growth was seen in patients with alopecia universalis. Short vellus hair was significantly increased while yellow dots were significantly decreased after treatment.

PRP was found to be more effective in patchy alopecia than alopecia universalis while it was not effective in alopecia totalis. A significant regrowing hair was seen in patchy alopecia (70%) than alopecia universalis (30%). PRP led to significant hair regrowth of fully pigmented hair in AA lesions. Both short vellus hair and yellow dots were significantly decreased after PRP treatment.

Only 30% of control group showed a significant hair growth and they were all patchy alopecia, with a significant increase in short vellus hair and decrease in yellow dots after 3 months. The lowest significance of growing hair was observed in control group ($p = .005$). No hair growth was observed in other types of alopecia in this group.

Although both PRP and minoxidil 5% showed significant increase in hair growth, patients treated with PRP showed a significant decrease

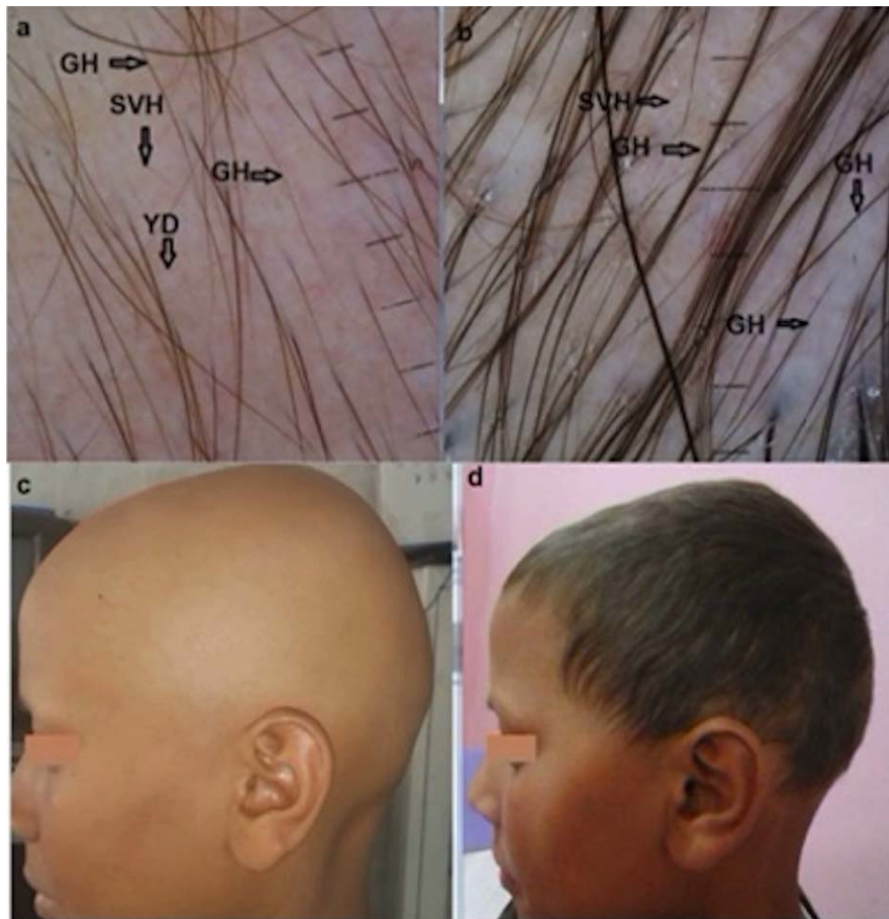


FIGURE 2 a–d: A 15-years-old male patient presented by alopecia universalis of 2-years. (a) Trichoscopy after 1 month of PRP treatment shows short vellus hairs (SVH), upright growing hair (GH) and yellow dots (YD). (b) Trichoscopy after 3 months shows upright growing hair (GH) and short vellus hairs (SVH). (c) Digital photo before PRP treatment. (d) A photo after 3 months of PRP treatment shows scalp, eye brows, and eye lashes were completely resolved

in short vellus hair, yellow dots, and dystrophic hair unlike patients treated with minoxidil and control who showed significant increase in short vellus hair mean. Patients treated with PRP had an earlier and better response than patients treated with minoxidil 5% in the form of hair regrowth, reduction of short vellus hair, and yellow dots (Table 1; Figures 1 and 2).

3 | DISCUSSION

Alopecia areata is a nonscarring hair loss that can affect scalp, beard, body, eyebrows, or eyelashes. It may be circumscribed, total, or universal (Finner, 2011). Trichoscopic findings of AA include yellow dots, dystrophic hair, black dots, exclamation mark hair, and growing hairs. Short vellus hair may also present (Ekiz, Sen, Rifaioglu, & Balta, 2013; Kose & Gulec, 2012; Rudnicka, Olszewska, & Rakowska, 2008).

The present study evaluated the efficacy of minoxidil and PRP in treatment of AA by clinical evaluation and dermoscopic findings. Trichoscopic findings evaluated include percentage of hair growth, short vellus hairs and yellow dots. We evaluated growing hair as a prognostic dermoscopic finding. Upright or coiled growing or hairs are a reliable sign for disease remission (Rudnicka et al., 2011).

Yellow dots are very characteristic and have been seen in all patients of our study. These are marked by distinctive array of yellow to yellow-pink, round, or polycyclic dots that vary in size and are uniform in color. Isolated yellow dots may be seen in androgenetic alopecia, trichotillomania, hypotrichosis simplex, and tinea capitis, so for the diagnosis of AA, other signs should be taken into account (Inui, 2011). Yellow dots represent keratinous plugs in AA while in androgenetic alopecia represent sebaceous debris (Rakowska, Slowinska, Kowalska-Oledzka, & Olszewska Mand Rudnicka, 2009).

In other work by Mane et al. (2011), they found that yellow dots and short vellus hairs help in differentiation of AA from other hair loss disorders. Abundant numbers of the yellow dots are seen in AA while androgenetic alopecia and trichotillomania have limited number of yellow dots.

Current treatment strategies of hair loss are mainly focused on promoting cellular proliferation and differentiation during the hair growth cycle. It has been postulated that minoxidil prolongs anagen and increases hair follicle size through stimulation of potassium channels and prostaglandins endoperoxide synthase-1 (Cervelli et al., 2014; Macdonald Hull, Wood, Hutchinson, Sladden, & Messenger, 2003).

In the present study, minoxidil showed a significant increase in upright growing hair, and significant increase in short vellus hair after

three months' treatment. These results concede with findings of Inui et al. (2007), who detected that clustered short vellus hair is inversely correlated with the severity of the disease.

Minoxidil was more effective in patchy alopecia than other types of AA such as ophiasis and alopecia totalis. It was noneffective in alopecia universalis. These results agree with early studies reported a significant hair regrowth in patchy alopecia in patients treated with topical minoxidil as compared with placebo (Messenger, McKillop, Farrant, McDonagh, & Sladden, 2012; Olsen et al., 2004). Another study compared 5 and 2% minoxidil in extensive AA, regrowth of hair occurred more frequently in those receiving 5% minoxidil but few subjects obtained a cosmetically worthwhile result. They found that minoxidil is ineffective in alopecia totalis and alopecia universalis (Lucy, Piacquadio, & Ditre, 2004).

The present study evaluated cases before and 3 months after treatment. Longer duration of follow up are needed as Ito (2012) stated that hair loss generally recurs after treatment is stopped because minoxidil does not change the perifollicular lymphoid infiltration even in improved cases of AA.

Activated autologous PRP has been reported to induce the proliferation of dermal papilla cells by up regulating FGF-7 and b-catenin as well as ERK and AKT signaling. Anagen-associated angiogenesis has been suggested as one of the important factors in active hair growth (Kwon, Pyo, & Oh, 2007; Li et al., 2012).

Shumes et al. (2015) found that as AA is characterized by an extensive inflammatory infiltrate, responsible for secretion of a variety of inflammatory cytokines. They supposed that the anti-inflammatory effects of PRP may be beneficial in this condition.

Cervelli et al. (2014) observed increase in the epidermal thickness and number of hair follicles two weeks after last PRP treatment compared to baseline value using microscopic evaluation.

Conceding with the above findings, our study showed significant hair regrowth in AA lesions. In addition to significant reduction in yellow dots and Short vellus hair percentage especially after PRP administration for 3 months. Also patients treated with PRP had an earlier response than patients treated with minoxidil in our study. PRP resulted in major improvements with patchy AA, less with alopecia universalis and found to be not effective with alopecia totalis.

Our results agree with those of Trink et al. (2013), who found that PRP administration led to major improvement in AA lesions and decreased the number of dystrophic hairs as assessed by dermoscopic photomicrographs.

Singh (2015) performed a prospective study to evaluate the efficacy of PRP in the treatment of chronic AA. None of their patients had any side effects, and all of them tolerated the procedure well. They concluded that PRP has a definite role in treating AA. Long-term follow-up studies are required to evaluate the rate of recurrence and to evaluate the efficacy of PRP treatment in recurrent AA.

4 | CONCLUSION

We concluded that PRP is more effective therapy for treatment of AA than minoxidil 5% in the same period of treatment. Although both

minoxidil and PRP showed a significant hair growth and decrease in yellow dots, PRP showed a significant decrease in short vellus hair while minoxidil showed an increase in short vellus hair. Moreover, PRP has no side effects such as those of minoxidil 5%. We also concluded that trichoscopy is valuable in diagnosis and follow up of AA. Further studies with longer duration of follow up are needed to evaluate the recurrence after treatment.

CONFLICT OF INTEREST

No conflict of interest.

REFERENCES

- Abraham, L. S., Torres, F. N., & Azulay-Abulafia, L. (2010). Dermoscopic clues to distinguish trichotillomania from patchy alopecia areata. *Anais Brasileiros de Dermatologia*, 85(5), 723–726.
- Alkhalifah, A., Alsantali, A., Wang, E., McElwee, K. J., & Shapiro, J. (2010). Alopecia areata update: Part I. Clinical picture, histopathology, and pathogenesis. *Journal of the American Academy of Dermatology*, 62, 177–188.
- Alsantali, A. (2011). Alopecia areata: A new treatment plan. *Clinical, Cosmetic and Investigational Dermatology*, 4, 107–115.
- Amin, S. S., & Sachdeva, S. (2013). Alopecia areata: An update. *Journal of Pakistan Association of Dermatologists*, 23(2), 209–220.
- Arshdeep Kumaran, M. S. (2014). Platelet-rich plasma in dermatology: Boon or a bane. *Indian Journal of Dermatology, Venereology and Leprology*, 80, 5–14.
- Campos-do-Carmo, G., & Ramos-e-Silva, M. (2008). Dermoscopy: Basic concepts. *International Journal of Dermatology*, 47, 712–719.
- Cervelli, V., Garcovich, S., Bielli, A., Cervelli, G., Curcio, B. C., Scioli, M. G., ... Gentile, P. (2014). The effect of autologous activated platelet rich plasma (AA-PRP) injection on pattern hair loss: Clinical and histomorphometric evaluation. *Bio Med Research International*, 2014, 1–9.
- Ekiz, O., Sen, B. B., Rifaioğlu, E. N., & Balta, I. (2013). Trichoscopy in paediatric patients with tinea capitis: A useful method to differentiate from alopecia areata. *Journal of the European Academy of Dermatology and Venereology*, 31(1), 93–108.
- Finner, A. M. (2011). Alopecia areata: Clinical presentation, diagnosis, and unusual cases. *Dermatologic Therapy*, 24, 348–335.
- Gilhar, A., Etzioni, A., & Paus, R. (2012). Alopecia areata. *The New England Journal of Medicine*, 366, 1515–1525.
- Inui, S. (2011). Trichoscopy for common hair loss diseases: Algorithmic method for diagnosis. *The Journal of Dermatology*, 38, 71–75.
- Inui, S., Nakajima, T., & Itami, S. (2007). Dry dermoscopy in clinical treatment of alopecia areata. *The Journal of Dermatology*, 34(9), 635–639.
- Inui, S., Nakajima, T., Nakagawa, K., & Itami, S. (2008). Clinical significance of dermoscopy in alopecia areata: Analysis 300 cases. *International Journal of Dermatology*, 47, 688–693.
- Ito, T. (2012). Advances in the management of alopecia areata. *The Journal of Dermatology*, 39, 11–17.
- Kose, O. K., & Gulec, A. T. (2012). Clinical evaluation of alopecias using a handheld dermatoscope. *Journal of the American Academy of Dermatology*, 67(2), 206–214.
- Kwon, O. S., Pyo, H. K., & Oh, Y. J. (2007). Promotive effect of minoxidil combined with all-trans retinoic acid (tretinoin) on human hair growth in vitro. *Journal of Korean Medical Science*, 22(2), 283–289.

- Li, Z. J., Choi, H. I., Choi, D. K., Sohn, K. C., Im, M., Seo, Y. J., . . . Lee, Y. (2012). Autologous platelet-rich plasma: A potential therapeutic tool for promoting hair growth. *Dermatologic Surgery*, 38(11), 1040–1046.
- Lucy, A. W., Piacquadio, D. J., & Ditre, C. M. (2004). A randomized placebo-controlled trial of 5% and 2% topical minoxidil solutions in the treatment of female pattern hair loss. *Journal of the American Academy of Dermatology*, 50, 541–553.
- Macdonald Hull, S. P., Wood, M. L., Hutchinson, P. E., Sladden, M., & Messenger, A. G. (2003). Guidelines for the management of alopecia areata. *British Journal of Dermatology*, 149, 692–699.
- Mane, M., Nath, A. K., & Thappa, D. M. (2011). Utility of dermoscopy in alopecia areata. *Indian Journal of Dermatology*, 56(4), 407–411.
- McElwee, K., & Sinclair, R. (2008). Hair physiology and its disorders. *Drug Discovery Today: Disease Mechanisms*, 5, 163–171.
- Messenger, A. G., McKillop, J., Farrant, P., McDonagh, J., & Sladden, M. (2012). Guidelines for the management of alopecia areata. *British Association of Dermatologists*, 166, 916–926.
- Olsen, E. A., Hordinsky, M. K., Price, V. H., Roberts, J. L., Shapiro, J., Canfield, D., . . . Norris, D. (2004). National alopecia areata foundation. Alopecia areata investigational assessment guidelines. Part II. National Alopecia Areata Foundation. *Journal of the American Academy of Dermatology*, 51, 440–447.
- Paus, R. (1996). Control of the hair cycle and hair disease as cycling disorders. *Current Opinion in Dermatology*, 3, 248–258.
- Perera, E., Yip, L., & Sinclair, R. (2014). Alopecia areata. *Hair Therapy & Transplantation*, 4, 118.
- Rakowska, A., Slowinska, M., Kowalska-Oledzka, E., & Olszewska Mand Rudnicka, L. (2009). Dermoscopy in female androgenic alopecia: Method standardization and diagnostic criteria. *International Journal of Trichology*, 1(2), 123–130.
- Rodriguez, T. A., & Duvic, M. (2008). Onset of alopecia areata after Epstein-Barr virus infectious mononucleosis. *Journal of the American Academy of Dermatology*, 59, 137–139.
- Ross, E. K., Vincenzi, C., & Tosti, A. (2006). Video dermoscopy in the evaluation of hair and scalp disorders. *Journal of the American Academy of Dermatology*, 55, 799–806.
- Rudnicka, L., Olszewska, M., & Rakowska, A. (2008). Trichoscopy: A new method for diagnosing hair loss. *Journal of drugs in dermatology*, 7, 651–654.
- Rudnicka, L., Olszewska, M., Rakowska, A., & Slowinska, M. (2011). Trichoscopy update. *Journal of Dermatological Case Reports*, 5(4), 82–88.
- Shumez, H., Prasad, P. V. S., Kaviarasan, P. K., & Deepika, R. (2015). Intralesional platelet rich plasma vs intralesional triamcinolone in the treatment of alopecia areata: A comparative study. *International Journal of Medical Research & Health Sciences*, 1, 118–122.
- Singh, S. (2015). Role of platelet-rich plasma in chronic alopecia areata. *Indian Journal of Plastic Surgery*, 48, 57–59.
- Tosti, A. (2007). Dermoscopy of hair and scalp disorders with clinical and pathological correlations (pp. 1–14). London: Informa Healthcare.
- Trink, A., Sorbellini, E., Bezzola, P., Rodella, L., Rezzani, R., Ramot, Y., & Rinaldi, F. (2013). A randomized, double-blind, placebo- and active-controlled half-head study to evaluate the effects of platelet-rich plasma on alopecia areata. *British Journal of Dermatology*, 169(3), 690–694.
- Wasserman, D., Guzman-Sanchez, D. A., Scott, K., & McMichael, A. (2007). Alopecia areata. *International Journal of Dermatology*, 46, 121–131.
- Zonunsanga, (2015). Alopecia areata: Medical treatments. *Our Dermatology Online*, 6(1), 86–91.